

## Mucosectomy as Treatment for Intractable Pouchitis Symptoms Following Ileal Pouch Anal Anastomosis

Glenn Ault\*

Andreas Kaiser†

Petar Vukasin‡

Robert Beart Dr. \*\*

\*ault@usc.edu

†University of Southern California, Kaiser@usc.edu

‡University of Southern California, Vukasin@pacbell.net

\*\*rbeart@usc.edu

# Mucosectomy as Treatment for Intractable Pouchitis Symptoms Following Ileal Pouch Anal Anastomosis

Glenn Ault, Andreas Kaiser, Petar Vukasin, and Robert Beart Dr.

## Abstract

### ABSTRACT:

**Purpose:** To investigate the role of completion mucosectomy for patients suffering from intractable diarrhea, tenesmus and pain after a stapled ileal pouch anal anastomosis (IPAA) procedure. A small percentage of patients develop disabling bowel symptoms after the IPAA procedure and are diagnosed with pouchitis. We hypothesized that a number of these patients may have ulcerative colitis in the residual rectal mucosa that may be responsible for these symptoms.

**Methods:** Sixteen (16) patients who underwent double-stapled IPAA and had symptoms of intractable pouchitis underwent subsequent residual rectal mucosectomy with pouch advancement. Data were collected from medical records and telephone interviews with the patient. Follow-up was incomplete on two patients who were then excluded from data analysis.

**Results:** Fourteen patients (10M, 4F) ranging from 19-55 years in age (mean=38) were included in the analysis. Mean follow-up was 17 months (range= 2-29, median=19). Prior to mucosectomy, 100%, 38% and 23% of patients had been treated with antibiotics, bismuth, and probiotics, respectively. 71% of patients reported improvement in their symptoms after mucosectomy. There were significant decreases in both the number of bowel movements during the day (14.4( $\pm$ 9.3) to 7.9( $\pm$ 4.3),  $p < 0.01$ ) and night (5.7( $\pm$ 3.2) to 2.8( $\pm$ 2.2),  $p < 0.01$ ). Following mucosectomy there was significant improvement in stool quality ( $p = 0.02$ ) and a decrease in the number of patients experiencing bloody stools (64% to 29%,  $p = 0.07$ ). These results were more marked in patients whose rectal cuff has histopathologic evidence of inflammatory bowel disease. Anal stricture occurred in 43% of patients post-operatively, and all of these were successfully managed with dilations in the office setting.

**Conclusion:** Chronic ulcerative colitis of the native rectal mucosal remnant is an important consideration in those patients who present with symptoms compatible with intractable pouchitis after a double-stapled IPAA. Mucosectomy provides relief in the majority of such patients and is an important addition to the surgeon's armamentarium in the management of these debilitating symptoms.

**KEYWORDS:** ileoanal, pouchitis, complication

# **Mucosectomy as Treatment for Intractable Pouchitis Symptoms Following Ileal Pouch Anal Anastomosis**

---

Glenn Ault, M.D. Swarna Balasubramaniam, M.D.,  
Petar Vukasin, M.D., Andreas Kaiser, M.D., and Robert W. Beart, Jr., M.D.

Department of Colon and Rectal Surgery  
University of Southern California, Keck School of Medicine  
Los Angeles, CA 90033

## **Correspondence to:**

Glenn Ault., MD  
Department of Colorectal Surgery  
University of Southern California  
1441 Eastlake Avenue, Suite 7418  
Los Angeles, CA 90033

Phone: (323) 865-3690  
Fax: (323) 865-3671  
Email – rbeart@usc.edu

**ABSTRACT:**

**Purpose:** To investigate the role of completion mucosectomy for patients suffering from intractable diarrhea, tenesmus and pain after a stapled ileal pouch anal anastomosis (IPAA) procedure. A small percentage of patients develop disabling bowel symptoms after the IPAA procedure and are diagnosed with pouchitis. We hypothesized that a number of these patients may have ulcerative colitis in the residual rectal mucosa that may be responsible for these symptoms.

**Methods:** Sixteen (16) patients who underwent double-stapled IPAA and had symptoms of intractable pouchitis underwent subsequent residual rectal mucosectomy with pouch advancement. Data were collected from medical records and telephone interviews with the patient. Follow-up was incomplete on two patients who were then excluded from data analysis.

**Results:** Fourteen patients (10M, 4F) ranging from 19-55 years in age (mean=38) were included in the analysis. Mean follow-up was 17 months (range= 2-29, median=19). Prior to mucosectomy, 100%, 38% and 23% of patients had been treated with antibiotics, bismuth, and probiotics, respectively. 71% of patients reported improvement in their symptoms after mucosectomy. There were significant decreases in both the number of bowel movements during the day ( $14.4(\pm 9.3)$  to  $7.9(\pm 4.3)$ ,  $p < 0.01$ ) and night ( $5.7(\pm 3.2)$  to  $2.8(\pm 2.2)$ ,  $p < 0.01$ ). Following mucosectomy there was significant improvement in stool quality ( $p = 0.02$ ) and a decrease in the number of patients

experiencing bloody stools (64% to 29%,  $p=0.07$ ). These results were more marked in patients whose rectal cuff has histopathologic evidence of inflammatory bowel disease. Anal stricture occurred in 43% of patients post-operatively, and all of these were successfully managed with dilations in the office setting.

**Conclusion:** Chronic ulcerative colitis of the native rectal mucosal remnant is an important consideration in those patients who present with symptoms compatible with intractable pouchitis after a double-stapled IPAA. Mucosectomy provides relief in the majority of such patients and is an important addition to the surgeon's armamentarium in the management of these debilitating symptoms.

**BACKGROUND:**

The IPAA (Ileal Pouch Anal Anastomosis) procedure has vastly improved the quality of life for patients who require a proctocolectomy for treatment of ulcerative colitis.<sup>1,2</sup> The IPAA procedure was initially described as a total proctocolectomy with rectal mucosectomy and hand-sewn anastomosis of the ileal pouch to the dentate line. The procedure was altered by the introduction of the bowel staplers. Use of the endoluminal circular staple allows the ileal pouch to be anastomosed to the most distal portion of the rectal mucosa above the dentate line. Staplers have made the procedure easier to perform and patients may have a better functional outcome after a stapled anastomosis as compared to a hand-sewn one with rectal mucosectomy.<sup>3</sup>

Despite the overall excellent functional outcome, about 5% of patients will suffer from episodes of pouchitis refractory to medical treatments<sup>4</sup> after undergoing the IPAA procedure for ulcerative colitis. Intractable pouchitis is a source of pouch loss in about 1% of patients.<sup>5</sup> More recently, it has been recognized that there can be significant inflammation in the residual rectal mucosa after the double-stapled technique; this condition has been termed cuffitis.<sup>6</sup> The symptoms of cuffitis can cause symptoms mimicking pouchitis.<sup>7</sup> A study from the Cleveland Clinic found inflammation of the rectal cuff in 22% of the patients they reviewed.<sup>8</sup> Recognizing and treating cuffitis may decrease the rate of pouch loss in patients after IPAA, which was 9% (from all causes) at 10 years after IPAA in one Mayo Clinic study.<sup>9</sup>

We hypothesized that cuffitis may be responsible for the symptoms we had been treating in patients diagnosed with medically intractable pouchitis and by performing mucosal stripping of the rectal remnant in these patients, we hoped to alleviate symptoms of pouchitis and eliminate this diagnostic variable. We present a retrospective review of our series of patients who had undergone mucosectomy, to determine if their symptoms had been altered by the procedure.

### **PATIENTS AND METHODS:**

The case records of the surgeons in the Department of Colon and Rectal Surgery at the Keck School of Medicine at the University of Southern California were reviewed to identify patients who had a mucosectomy procedure after originally undergoing an IPAA procedure for ulcerative colitis. A total of sixteen patients were identified who had their procedure between January 2000 and September 2002. Data regarding details of their procedures and pathology results were obtained from their medical records.

The surgical technique includes placing the patient in lithotomy and excising all visible rectal mucosa, from the dentate line to and including the previous staple line. Exposure is facilitated by a Lone Star<sup>®</sup> retractor. The pouch is then sutured full thickness to the dentate line with interrupted 2-0 vicryl sutures.

The patients were then invited to participate in a verbal survey to answer questions regarding their bowel function before and after the mucosectomy. The lead author conducted all telephone surveys. Questions asked included the average number of

bowel movements during daytime and nighttime, stool quality and the presence of abdominal pain and cramping. Patients were asked about need for current medical treatments for these symptoms and their effectiveness both before and after mucosectomy. Inquiries were also made regarding fecal incontinence symptoms such as urgency, accidents, soilage and the use of a protective pad. The protocol for this study was reviewed and approved by the University of Southern California Health Campus Institutional Review Board.

### **STATISTICS:**

Statistical analysis used on the data includes the Student's paired t-test to compare the number of bowel movements patients experienced before and after the mucosectomy. Wilcoxon's chi-squared analysis was used to summarize the differences in stool quality. The McNemar's paired chi-squared test was used to evaluate the difference in the proportions of patients experiencing a difference in symptoms prior to and after mucosectomy in bloody bowel movements, abdominal pain, cramping and incontinence symptoms.

### **RESULTS:**

Of the sixteen (16) identified patients, one could not be contacted and another declined to participate in the study, leaving fourteen (14) suitable for evaluation. Patient ages ranged from 19 to 55 (mean 38) years old. There were 10 men and 4 women in the group. Twelve of the fourteen patients had had their IPAA procedure at our institution, while two were referred from elsewhere. All patients underwent excision of the rectal

cuff with advancement of the pouch to the dentate line by the surgeons involved in this study. There were no intraoperative complications. All excised tissue was sent to the surgical pathology laboratory for permanent section and confirmed as rectal mucosa with varying degrees of inflammation.

All patients in this study had intractable pouchitis symptoms that were unresponsive to medical treatments which included antibiotics, bismuth, probiotics or a combination of the three. Prior to mucosectomy 100%, 38%, and 23% of patients had been treated with antibiotics, bismuth and probiotics, respectively. After the mucosectomy procedure, 23% of patients had resolved their symptoms. After mucosectomy patients were using the same treatments at similar rates, but with significantly better results. The overall quality of their symptoms (pain, cramping, diarrhea) was less severe with 71% of patients reporting that the procedure improved their symptoms. [Figure 1]

Patients were asked to report on the average number of bowel movements experienced both during the day and at night before and after the mucosectomy. The number of daytime bowel movements decreased from 14.4 (+/-9.3) to 7.9(+/-4.3) [p value <0.01] and the number of stools at night decreased from 5.7(+/-3.2) to 2.8(+/-2.2) [p value = 0.01]. They were also queried regarding the quality of their stool (liquid, semi-formed, or formed) and there was overall improvement in stool quality (p=0.02). The number of patients experiencing bloody stools also decreased from 64% (9/14) prior to mucosectomy to 28% (4/14) [p=0.07] after the procedure. A summary of patient reported results regarding changes in bowel habits before and after mucosectomy is depicted in Table 1. Anal stricture, defined as an anus not admitting a surgeon's index

finger on rectal exam, occurred in 43% (6/14) of patients post-mucosectomy. All of these patients had their strictures successfully dilated and managed in the office setting.

All excised rectal mucosal tissue was sent to the surgical pathology laboratory and review of this tissue reveals inflammation in 12 of 14 patients with characteristics of inflammatory bowel disease being clearly present in 10 specimens. [Table 2]

Correlation of the histopathology to individual patient reported improvements in stool quality is depicted in Figure 2. The decrease in the mean number of bowel movements experienced by patients both prior to and after mucosectomy was also stratified by the pathology results of their excised mucosal tissue. Overall, patients had a decrease of  $-8.6 \pm 11.7$  ( $p=0.01$ ) bowel movements per 24-hour period as a result of this procedure. Those patients who had rectal cuffs with IBD inflammatory changes ( $n=10$ ) had a decrease of  $-9.8 \pm 13.9$  ( $p=0.09$ ) bowel movements as compared to a net decrease of  $-6.0 \pm 3.6$  ( $p=0.029$ ) in patients without inflammatory changes seen in the rectal cuff pathology ( $n=4$ ). [Figure 3] The number of patients reporting blood in the bowel movements decreased from 9 to 4 as a result of the mucosectomy procedure [Table 1]. These individual results, when separated by the rectal cuff pathology, reveal that only patients with IBD changes in the rectal cuff experienced relief from bloody bowel movements after mucosectomy. [Figure 4]

## **DISCUSSION:**

The IPAA procedure has become the operation of choice for patients with ulcerative colitis requiring a proctocolectomy. Despite the excellent functional outcome in a

majority of patients, pouchitis symptoms remain a disabling complication in some. This review indicates that patients with medically intractable pouchitis symptoms can be helped by mucosectomy of the remnant rectal cuff after a double-stapled IPAA. Patients experienced both quantitative and qualitative improvement in their symptoms as evidenced respectively by a decrease in number of daytime and nighttime bowel movements and decreases in pain, incontinence and a progression to more solid stools. 43% of patients (6/14) had anal strictures post-operatively that were diagnosed in the office when the strictured anus could not admit a finger for digital examination. All of these were treated with dilatation either in the office or at home or both and were not the source of any other morbidity.

Review of the histopathology of the excised rectal cuff tissue (Table 2) reveal that the majority of the tissue specimens (10/14) had evidence of inflammation consistent with inflammatory bowel disease. This information cross-indexed with individual patient's improvements in stool quality and quantity suggests that patients with residual inflammatory bowel disease in the rectal cuff were most likely to be helped by the mucosectomy. The improvement in stool quality was significant overall ( $p=0.02$ ). A careful review of those patients with unchanged stool quality (6 patients) reveals that 67% did not have evidence of inflammatory bowel disease in their rectal cuff. [Figure 1] Analysis of the stool quantity data reveals a similar trend. [Figure 3] The patients with inflammatory bowel disease pathologically present in the rectal cuff had greater decreases in number of bowel movements as compared to those with benign histopathology. Similar analysis of patients with blood in bowel movements reveals that

all of those with relief of this symptom had IBD in the mucosal cuff. [Figure 4]. Overall, 71% of patients felt that the mucosectomy was of benefit to them. A greater number of patients with IBD in their rectal mucosal cuff (80%, 8/10) answered affirmatively to this question as compared to the group as a whole.

This data suggests that the residual inflammatory bowel disease in the rectal cuff is contributory to the pouchitis symptoms experienced by these patients. The recent study from the Cleveland Clinic treating cuffitis with topical mesalamine resulted in similar improvements.<sup>7</sup> Rectal mucosectomy offers a more permanent treatment alternative for rectal cuffitis with minimal morbidity. It would be reasonable to hypothesize that those patients with good response to mesalamine treatment may be the best candidates for a mucosectomy.

## **CONCLUSION:**

Rectal mucosal cuff inflammation (cuffitis) secondary to residual inflammatory bowel disease is an important cause of medically intractable pouchitis-like symptoms.

Mucosectomy is a relatively simple procedure that provides relief in a majority of these patients with minimal morbidity and is an important addition to the surgeon's armamentarium in the treatment of these debilitating symptoms.

**FIGURE 1****Did Surgery Improve Symptoms?**

		<b>Tissue Pathology</b>	
		<b>IBD</b>	<b>No IBD</b>
<b>Mucosectomy</b>	<b>Helped</b>	8 (80%)	2 (20%)
	<b>No Help</b>	2	2

**Overall, 71% of patients felt surgery to be of benefit**

**TABLE 1****Summary of Results**

	Pre-Mucosectomy	Post-Mucosectomy	P value
BMs/day	14.4±9.3	7.8±4.3	<0.01
BMs/night	5.7±3.2	2.8±2.2	0.01
(Y/N)			
Bloody BMs	9/14 (64%)	4/14 (28%)	0.07
Abd Pain	9/14 (64%)	5/14 (36%)	0.13
Tenesmus/Cramping	7/14 (50%)	4/14 (29%)	0.25
Accidents	10/13(77%)	7/13 ( 54%)	0.25
Soiling	10/13(77%)	6/13 (46%)	0.13
Stricture		6/14 (43%)	N/A

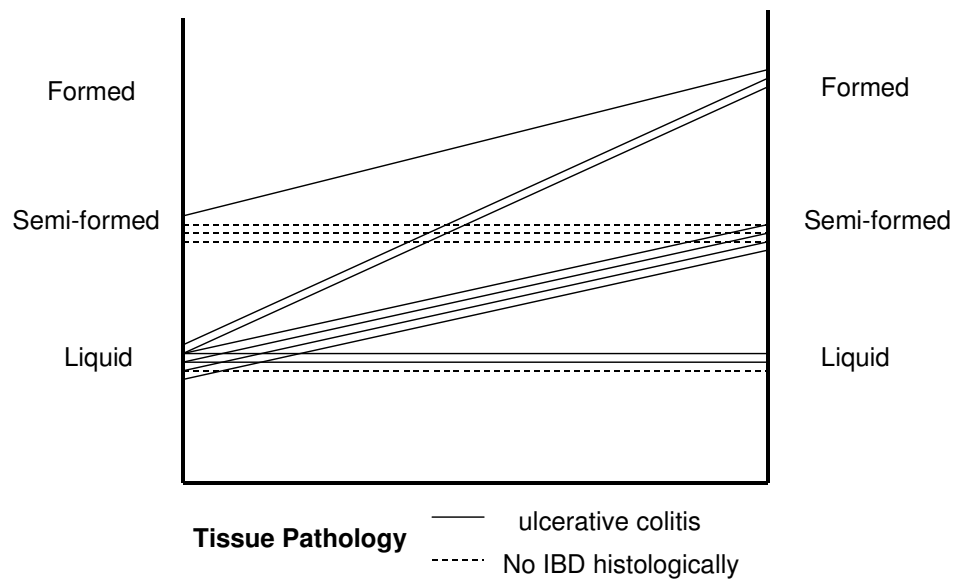
**TABLE 2**

**Improvement in Stool Quality Correlated With  
Rectal Cuff Histopathology**

<b>Patient</b>	<b>Pre</b>	<b>Post</b>	<b>Histopathology</b>
1	Liquid	Formed	active ulcerative colitis
2	Semi-Formed	Formed	inflammation c/w IBD
3	Liquid	Liquid	inflammation c/w IBD
4	Liquid	Liquid	hyperplasia
5	Semi-Formed	Semi-Formed	focal cryptitis
6	Liquid	Semi-Formed	active ulcerative colitis
7	Semi-Formed	Semi-Formed	chronic inflammation
8	Liquid	Formed	active ulcerative colitis
9	Liquid	Semi-Formed	ulcerative colitis
10	Liquid	Liquid	active ulcerative colitis
11	Semi-Formed	Semi-Formed	atrophic colonic mucosa
12	Liquid	Semi-Formed	active ulcerative colitis
13	Liquid	Semi-Formed	chronic ulcerative colitis
14	N/A	N/A	active ulcerative colitis

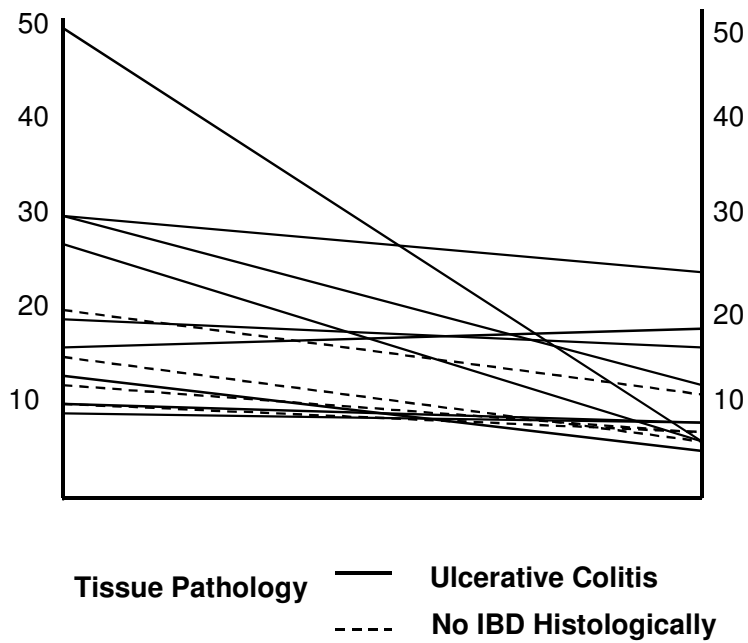
FIGURE 2

**Changes in Stool Quality  
Before and After Mucosectomy**



**FIGURE 3**

**Change in Number of BMs  
Before and After Mucosectomy**



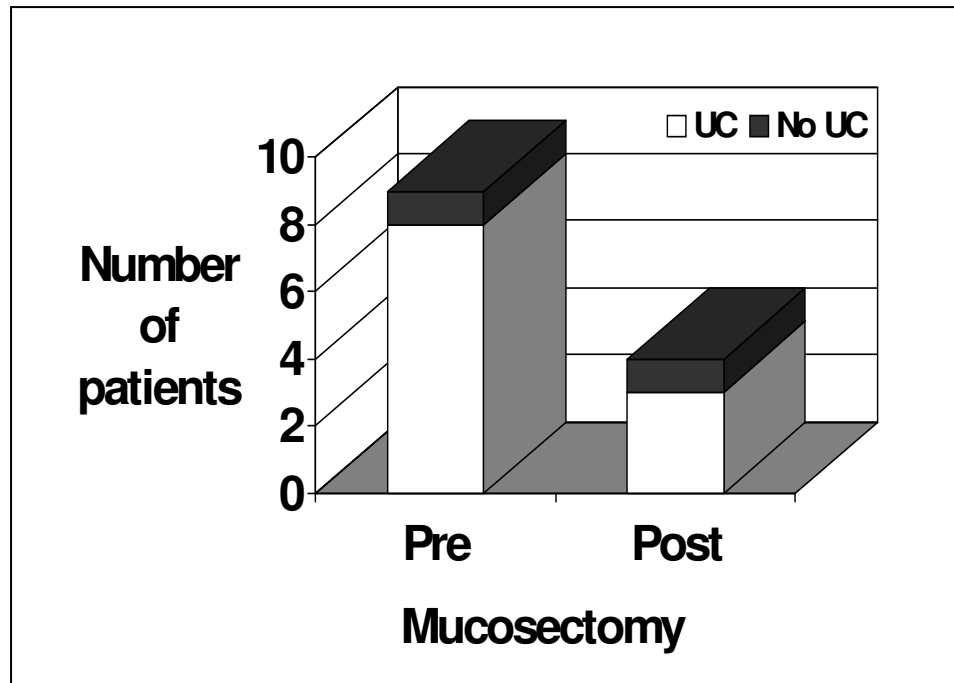
**All patients: mean =  $-8.6 \pm 11.7$ ,  $p=0.001$**

**UC patients: mean =  $-9.8 \pm 13.9$ ,  $p=0.009$**

**Non UC patients: mean =  $-6.0 \pm 3.6$ ,  $p=0.029$**

**FIGURE 4**

**Decrease in Patients with Bloody BMs  
By Histopathology**



## REFERENCES

1. Fazio, V.W., O’Riordan, M.G. et al Long-term Functional Outcome and Quality of Life After Stapled Restorative Proctocolectomy, *Annals of Surgery*. **230**: 575-86, 1999.
2. Ko, C.Y., Rusin, L.C. et al Long-Term Outcomes of the Ileal Pouch Anal Anastomosis: The Association of Bowel Function and Quality of Life 5 Years after Surgery, *J Surg Research*. **98**: 102-7, 2001.
3. Remzi F.H., Church, J.M. et al Mucosectomy vs Stapled Ileal Pouch-Anal Anastomosis in Patients with Familial Adenomatous Polyposis, *DCR*. **44**: 1590-96, 2001.
4. Nicholls, R.J. and Banerjee, A.K. Pouchitis: Risk Factors, Etiology, and Treatment. *World Journal of Surgery*. **22**:347-351, 1998.
5. Stocchi, L. and Pemberton, J. Pouch and Pouchitis. *Gastroenterology Clinics of North America*. **30**:223-241, 2001.
6. Thompson-Fawcett M.W., Mortensen, N.J. and B.F. Warren. “Cuffitis” and inflammatory changes in the columnar cuff, anal transitional zone, and ileal reservoir after stapled pouch-anal anastomosis, *DCR*. **42**: 348-55, 1999.
7. Shen, B., Lashner, B.A. et al. Treatment of Rectal Cuff Inflammation (Cuffitis) in Patients with Ulcerative Colitis Following Restorative Proctocolectomy and Ileal Pouch-Anal Anastomosis, *Am J Gastroenterology*. **99**: 1527-31, 2004.
8. Lavery, I.C., Sirimarco M.T et al Anal Canal Inflammation After Ileal Pouch-Anal Anastomosis, *DCR*. **38**: 803-806, 1995.
9. Meagher, A.P., Farouk, R. et al J ileal pouch-anal anastomosis for chronic ulcerative colitis: complications and long-term outcome in 1301 patients. **85**: 800-803, 1998.